

# Maxillary First Molar with Seven Root Canals Diagnosed with Cone-Beam Computed Tomography Scanning: A Case Report

Jojo Kottoor, BDS,\* Natanasabapathy Velmurugan, MDS,\* Rajmohan Sudha, MDS,\* and Senthilkumar Hemamalathi, MDS\*

## Abstract

**Introduction:** The purpose of this article was to emphasize the importance of having a thorough knowledge about the root canal anatomy. **Methods:** This case report presents the endodontic management of a maxillary first molar with three roots and seven canals. The clinical detection of the seven canals was made using a surgical operating microscope and confirmed using cone-beam computed tomography (CBCT) scanning. **Results:** CBCT axial images showed that both the palatal and distobuccal root have a Vertucci type II canal pattern, whereas the mesiobuccal root showed a Sert and Bayirli type XV canal configuration. **Conclusion:** This report describes and discusses the variation in canal morphology of maxillary first molar and the use of latest adjuncts in successfully diagnosing and negotiating them. (*J Endod* 2010;36:915–921)

## Key Words

Cone beam computerized tomography scanning, maxillary first molar, seven root canals

From the \*Department of Conservative Dentistry and Endodontics, Meenakshi Ammal Dental College and Hospital, Tamil Nadu, India.

Address requests for reprints to Dr Jojo Kottoor, Department of Conservative Dentistry and Endodontics, Meenakshi Ammal Dental College and Hospital, Alapakkam Main Road, Maduravoyal, Chennai, Tamil Nadu, India 600 095. E-mail address: drkottooran@gmail.com. 0099-2399/\$0 - see front matter

Copyright © 2010 American Association of Endodontists. doi:10.1016/j.joen.2009.12.015

The morphology of the permanent maxillary first molar has been reviewed extensively. The root canal anatomy of maxillary first molars has been described as three roots with three canals, and the commonest variation is the presence of a second mesiobuccal canal. The incidence of second mesiobuccal canal has been reported to be between 18% and 96.1% (1, 2). Other variations include one (3), four (4), and five (5) roots and unusual morphology of root canal systems within individual roots. Case reports with five (6) and six (7) root canals or with a C-shaped canal configuration (8) have also been reported earlier. Martínez-Berná and Ruiz-Badanelli (9) reported six root canals with three mesiobuccal, two distobuccal, and one palatal, whereas de Almeida et al (7) and Bond et al (10) reported six root canals with two mesiobuccal, two distobuccal, and two palatal. Maggiore et al (11) reported the maxillary first molar having six canals with two mesiobuccal, three palatal, and one distobuccal, whereas Adanir (12) reported a clinical case having four roots (mesiobuccal, mesiopalatal, distobuccal, and palatal) and six canals with one mesiobuccal, two mesiopalatal, two distobuccal, and one palatal. Alavi et al (13) and Thomas et al (14) reported the incidence of two canals in the distobuccal root as 1.90% and 4.30%, respectively, and few other case reports have noted two canals in the distobuccal root (5, 8, 10, 15). Case reports of maxillary first molar with unusual canal morphology are summarized in Table 1. The incidence of two root canals in the palatal root of maxillary molars has been reported to be 2% to 5.1% (16). Of the various comprehensive maxillary first molar *ex vivo* studies in the dental literature, only Baratto Filho et al (17) reported a maxillary first molar with three roots and seven root canals. Of the 140 extracted maxillary first molars, only one tooth showed seven root canals in which three mesiobuccal canals, 3 distobuccal canals, and one palatal canal were identified. The present case report discusses the successful endodontic management of a maxillary first molar presenting with three roots and seven root canals. This unusual morphology was confirmed with the help of cone beam computerized tomography (CBCT) scans.

## Case Report

A 37-year-old man presented to the Department of Conservative Dentistry and Endodontics, Meenakshi Ammal Dental College, with the chief complaint of spontaneous toothache in his right posterior maxilla for 2 days. The pain intensified by thermal stimuli and on mastication. History revealed intermittent pain in the same tooth with hot and cold stimuli for the past 1 month. The patient's medical history was noncontributory. A clinical examination revealed a carious maxillary right first molar (tooth #3), which was tender to percussion. Palpation of the buccal and palatal aspect of the tooth did not reveal any tenderness. The tooth was not mobile and periodontal probing around the tooth was within physiological limits. Vitality testing of the involved tooth with heated gutta-percha (Dentsply Maillefer, Ballaigues, Switzerland) and dry ice (R C Ice; Prime Dental Products Pvt Ltd, Mumbai, India) caused an intense lingering pain, whereas electronic pulp stimulation (Parkel Electronics Division, Farmingdale, NY) caused a premature response. A preoperative radiograph revealed mesio-occlusal radiolucency, approaching the pulp space with periodontal ligament space widening in relation to the mesiobuccal root (Fig. 1A). From the clinical and radiographic findings, a diagnosis of symptomatic irreversible pulpitis with symptomatic apical periodontitis was made and endodontic treatment was suggested to the patient.

**TABLE 1.** Case Reports of Maxillary First Molars with Unusual Canal Morphology

Root configuration	No. of canals	Root canals anatomy			Other key information	Reference
		MB	DB	P		
1 root	1	Single canal			India, 48-year-old woman	Gopikrishna et al (2006) (3)
1 root	1	Single canal			Turkey, 36-year-old man	Cobankara et al (2008) (18)
1 root	1	Single canal			Spain; 45 year old Caucasian female	de la Torre et al (2008) (19)
2 roots	2	1	C-shaped canal		US, 37-year-old white man	Newton and McDonald (1984) (20)
2 roots	2	1	C-shaped canal		Belgium, 21-year-old white woman	De Moor (2002) (21)
2 roots	3	2	C-shaped canal		Belgium, 44-year-old white woman	
2 roots	3	2	C-shaped canal (bilateral)		Israel, 11-year-old white female	Dankner et al (1990) (8)
2 roots	4	C-shaped canal (trifurcate in the apical one-third)		1	Turkey, 28-year-old white woman	Yilmaz et al (2006) (22)
2 roots (1 palatal and fused buccal root)	3	2			Not identified	Malagnino et al (1997) (23)
2 roots (1 palatal and fused buccal root)	3	2			Brazil, 23-year-old woman	Fava (2001) (24)
2 roots (1 palatal and fused buccal root)	2	1			China, 50-year-old woman	Ma et al (2009) (25)
3 roots (2 palatal roots and fused buccal root)	4	2			India, 25-year-old woman	Gopikrishna et al (2008) (26)
3 roots	4	1	2	1	Germany, 36-year-old white man	Hulsmann (1997) (15)
3 roots	4	1	2	1	US, 38-year-old white woman	Chen and Karabucak (2006) (27)
3 roots	4	1	1	2	India, 45- and 25-year old men	Poorni et al (2008) (3 cases) (28)
3 roots	4	1	1	2	India, 23-year-old man	Aggarwal et al (2009) (29)
4 roots (MB, DB, MP, DP)	4	Mesiobuccal, distobuccal, mesiopalatal & distopalatal			Canada, white	Christie et al (1991) (2 cases) (30)
4 roots (MB, DB, MP, DP)	4	Mesiobuccal, distobuccal, mesiopalatal & distopalatal			US, 31-year-old man	Di Fiore (1999) (31)
4 roots (MB, DB, MP, DP)	4	Mesiobuccal, distobuccal, mesiopalatal & distopalatal			Brazil, 38-year-old Japanese woman	Baratto-Filho et al (2002) (32)

(Continued)

**TABLE 1.** (Continued)

Root configuration	No. of canals	Root canals anatomy			Other key information	Reference
		MB	DB	P		
4 roots (MB, DB, MP, DP)	4	Mesiobuccal, distobuccal, mesiopalatal & distopalatal			Brazil, 35-year-old man	Barbizam et al (2004) (5)
3 roots	5	2	1	2	US, 23-year-old white man	Cecic et al (1982) (33)
3 roots	5	2	1	2	Israel, 22-year-old white man	Holtzman (1997) (34)
3 roots	5	2	1	2	Canada, 42-year-old man	Johal (2001) (35)
3 roots	5	2	1	2	Germany, 21-year-old man	Holderrieth et al (2009) (36)
3 roots	5	3	1	1	Brazil, 15-year-old white man	Favieri et al (2006) (37)
3 roots	5	3	1	1	US, 18-year-old man	Ferguson et al. (2005) (6)
3 roots	5	3	1	1	US, 14-year-old white male	Beatty (1984) (38)
Presumably fusion of the tooth #3 and #4	5	3 buccal		2	Israel, 13-year-old female	Stabholz and Friedman (1983) (39)
3 roots	5	2	1	2 (bifurcation at middle third)	Germany, 32-year-old man	Holderrieth et al (2009) (36)
3 roots	5	1	1	3 (trifurcation in the apical third)	USA, 22-year-old woman	Wong (1991) (40)
3 roots	6	2	1	3 (trifurcation in the apical third)	US, 19-year-old black man	Maggiore et al (2002) (11)
3 roots	6	3	2	1	Spain, 10- and 17-year-old males	Martínez-Berná and Ruiz-Badanelli (1983) (3 cases) (9)
3 roots	6	2	2	2	US, 27-year-old black woman	Bond et al (1988) (10)
3 roots	6	2	2	2	Brazil, 26-year-old man	de Almeida-Gomes et al (2009) (7)
4 roots (MB, MP, P, DB)	6	Mesiobuccal, mesiopalatal, mesial, palatal, distopalatal, distobuccal			Turkey, 31-year-old white man	Adanir (2007) (12)

MB, mesiobuccal; DB, distobuccal; MP, mesiopalatal; DP, distopalatal.

## Case Report/Clinical Techniques

Radiographic evaluation of the involved tooth did not indicate any variation in the canal anatomy (Fig. 1A). The tooth was anesthetized with 1.8 mL (30 mg) 2% lignocaine containing 1:200,000 epinephrine (Xylocaine; AstraZeneca Pharma Ind Ltd, Bangalore, India.) followed by rubber dam isolation. An endodontic access cavity was established. Clinical examination with a DG-16 endodontic explorer (Hu-Friedy, Chicago, IL) revealed two canal openings in each of the distobuccal, mesiobuccal, and palatal root. During examination with a surgical operating microscope (Seiler Revelation, St Louis, MO), a third canal was located midway between the mesiobuccal and palatal orifices. Coronal enlargement was done with a nickel-titanium ProTaper series orifice shaper (Dentsply Maillefer, Ballaigues, Switzerland) to improve the straight-line access (Fig. 1B). The working length was determined with the help of an apex locator (Root ZX; Morita, Tokyo, Japan) and later confirmed using a radiograph. Multiple working length radiographs were taken at different angulations (Fig. 1C). However, the radiographs did not clearly reveal the number and morphology of root canal systems.

To confirm this unusual morphology, it was decided to perform CBCT imaging of the tooth. Access cavity was sealed with IRM cement (Dentsply De Trey GmbH, Konstanz, Germany). An informed consent was obtained from the patient, and a multislice CBCT scan of the maxilla was performed (Simulix Evolution; Nucletron, Chennai, India Pvt Ltd) with a tube voltage of 100 KV and a tube current of 8 mA. The involved tooth was focused, and the morphology was obtained in transverse, axial, and sagittal sections of 0.5-mm thickness. CBCT scan slices revealed seven canals (three mesiobuccal, two palatal, and two distobuccal) in the right maxillary first molar (Fig. 2A-D).

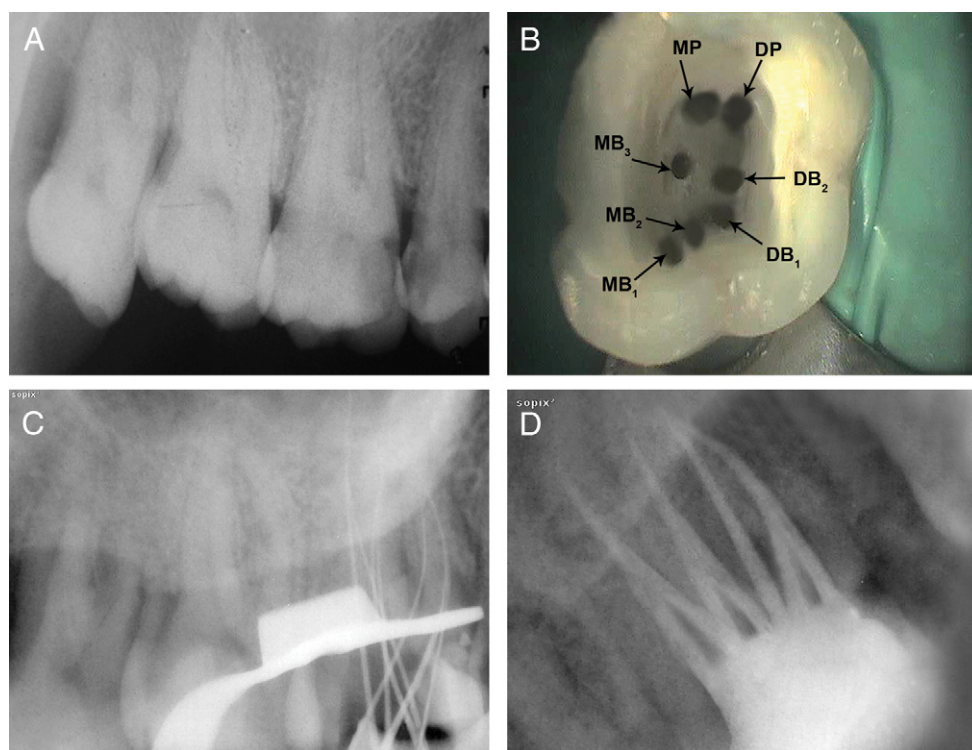
CBCT images provided valuable information regarding the canal configuration and confirmed the seven canals that were not clearly seen in the conventional radiograph. At the second appointment, the patient was asymptomatic. After administering 1.8 mL (36 mg) 2%

lignocaine with 1:200,000 epinephrine (Xylocaine), cleaning and shaping was performed under rubber dam isolation using ProTaper nickel-titanium rotary instruments (Dentsply Maillefer) with a crown-down technique. Irrigation was performed using normal saline, 2.5% sodium hypochlorite solution, and 17% EDTA; 2% chlorhexidine digluconate was used as the final irrigant. The canals were dried with absorbent points (Dentsply Maillefer), and obturation was performed using cold lateral compaction of gutta-percha (Dentsply Maillefer) and AH Plus resin sealer (Maillefer, Dentsply, Konstanz, Germany) (Fig. 1D). The tooth was then restored with a posterior composite resin core (P60; 3M Dental Products, St Paul, MN). The patient was advised a full-coverage porcelain crown and was asymptomatic during the follow-up period of 3 months.

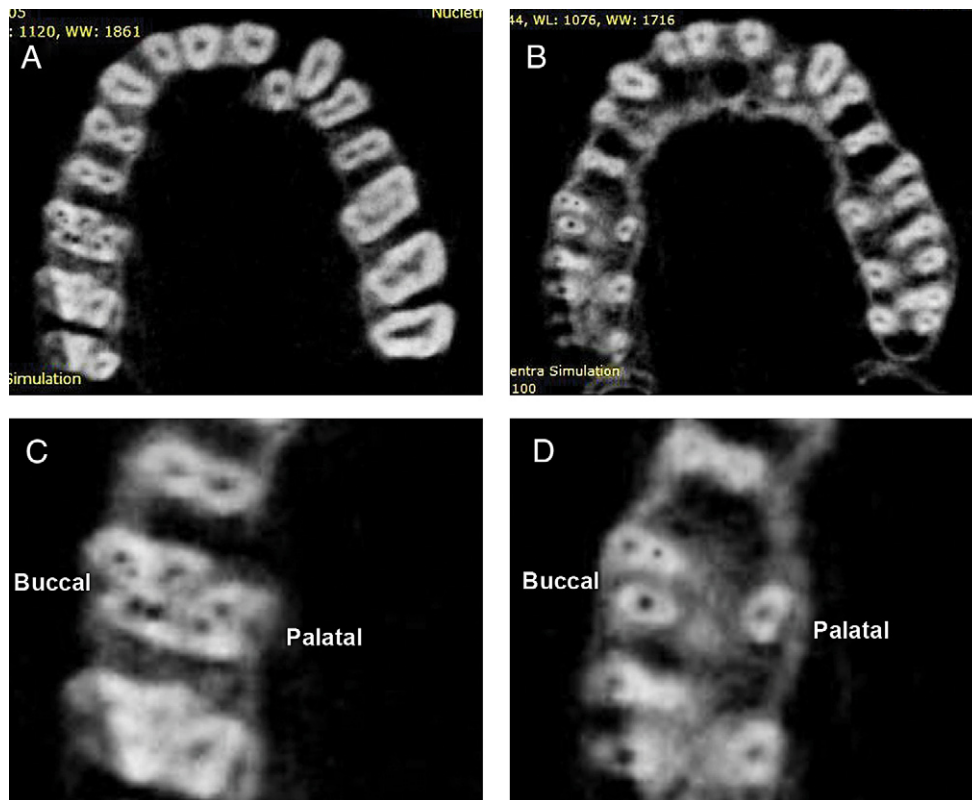
## Discussion

Radiographic examination is an essential component of the management of endodontic problems. The amount of information gained from conventional radiographs and digitally captured periapical radiographs is limited by the fact that the three-dimensional anatomy of the area being radiographed is compressed into a two-dimensional image (41). Newer diagnostic methods such as computerized axial tomography (CT) scanning greatly facilitate access to the internal root canal morphology. One distinct advantage of CT scanning over the conventional radiograph is that it allows the operator to look at multiple slices of tooth roots and their root canal systems (41). Robinson et al (42) reported that CT images identified a greater number of morphologic variations than panoramic radiographs. Although conventional CT scans produce a high level of detail in the axial plane, it is essential that the radiation dose is kept as low as reasonably achievable (43, 44).

The use of spiral computerized tomography (SCT) scans in dentistry has increased dramatically in the past 2 decades (30, 34,



**Figure 1.** (A) Preoperative radiograph of #3. (B) Access opening showing seven root canal orifices. (C) Working length radiograph of #3 in eccentric angulation. (D) Postobturation radiograph.



**Figure 2.** (A and B) CBCT images of #3 showing axial sections at the (A) cervical and (B) apical level. (C and D) Enlarged axial section CBCT images at the (C) cervical and (D) apical level showing three roots and seven canals.

45, 46). SCT scans acquire raw projection data with a spiral-sampling locus in a relatively short period. Without additional scanning time, these data can be viewed as conventional transaxial images such as multiplanar reconstructions or as three-dimensional reconstructions. With SCT scans, it is possible to reconstruct overlapping structures at arbitrary intervals, and, thus, the ability to resolve small subjects is increased. They have drastically reduced scan time and effective dosages, but they still are not as accurate and do not limit the dosage as low as reasonably achievable (47).

CBCT scanning is a relatively newer diagnostic imaging modality that has been used in endodontics for the effective evaluation of the root canal morphology (48–51). Additionally, CBCT technology aids in the diagnosis of endodontic pathosis, assessing root and alveolar fractures, analysis of resorptive lesions, identification of pathosis of nonendodontic origin, and presurgical assessment before root-end surgery (48, 50, 51). Matherne et al (52) investigated the use of CBCT scanning in identifying root canal systems and compared it with images obtained by using digital radiography. They concluded that CBCT images always resulted in the identification of greater number of root canal systems than digital images. Baratto Filho et al (17) evaluated the internal morphology of maxillary first molars by *ex vivo* and clinical assessments using operating microscope and CBCT scanning. He concluded that an operating microscope and CBCT scanning were important for locating and identifying root canals, and CBCT scanning can be used as a good method for initial identification of maxillary first molar internal morphology. The major advantages of CBCT scanning over the conventional CT scans are x-ray beam limitation (53), rapid scan time (50), and effective dose reduction (48); x-ray beam limitation is achieved by reducing the size of the irradiated area by collimation of the primary x-ray beam to the area of interest. It uses a cone-shaped

beam instead of the fan-shaped one used in regular CT scanners (48, 50). Rapid scan time (10–70 seconds) is because of its ability to acquire the whole three-dimensional volume of data in a single rotation (52). Published reports indicate that the effective dose (E) radiation is significantly reduced to an average of 36.9 to 50.3  $\mu\text{Sv}$ , a reported radiation dose equivalent to that needed for 4 to 15 panoramic radiographs. Patient's radiation exposure to a conventional CT is approximately 100 to 300  $\mu\text{Sv}$  for maxilla and 200 to 500  $\mu\text{Sv}$  for the mandible, whereas the radiation exposure (for both maxilla and mandible) to CBCT scanning is 34 to 102  $\mu\text{Sv}$  (54–57). Patient positioning modifications (tilting the chin) and the use of additional personal protection (thyroid collar) can substantially reduce the dosage by up to 40% (56).

Although there has been enormous interest, the current CBCT technology has limitations related to the “cone beam” projection geometry, detector sensitivity, and contrast resolution. These parameters create an inherent image “noise” that reduces image clarity and may limit adequate visualization of structures in the dentoalveolar region (58). Even though the use of CBCT scanning involves less radiation than conventional CT scanning, the radiation dose is still higher than regular conventional intraoral radiographs (56). At this point in time, CBCT scanning is limited to major metropolitan areas and is very expensive. Limitations also include medicolegal issues pertaining to the acquisition and interpretation of CBCT data (50).

In the present case, CBCT scanning was used for a better understanding of the complex root canal anatomy. CBCT axial images confirmed the presence of three roots and seven root canals, namely mesiobuccal<sub>1</sub> (MB<sub>1</sub>), mesiobuccal<sub>2</sub> (MB<sub>2</sub>), mesiobuccal<sub>3</sub> (MB<sub>3</sub>), distobuccal<sub>1</sub> (DB<sub>1</sub>), distobuccal<sub>2</sub> (DB<sub>2</sub>), mesiopalatal (MP) and distopalatal (DP). Contralateral tooth appeared to have normal root canal anatomy (Fig. 2A and B). CBCT axial images also showed that both

the palatal and distobuccal root present with a Vertucci type II canal pattern (59) (ie, two canal orifices join together and exit as one apical foramen), whereas the mesiobuccal root showed a Sert and Bayirli type XV canal configuration (60) (ie, MB<sub>1</sub> and MB<sub>2</sub> joined at the middle third of the root and exit in one apical foramen, whereas MB<sub>3</sub> has a separate canal orifice and exiting foramen) (Fig. 2C and D). The MB<sub>2</sub> is usually located palatally and mesially to the MB<sub>1</sub> (1), but in this particular case MB<sub>2</sub> was located between MB<sub>1</sub> and DB<sub>1</sub> (Fig. 1B) and this peculiar location was confirmed in the CBCT axial images (Fig. 2C and D). Thus, CBCT scanning was pivotal in the diagnosis of this unusual root canal system and towards its successful endodontic management.

## Conclusion

The present case report discusses the endodontic management of an unusual case of a maxillary first molar with three roots and seven canals and also highlights the role of surgical operating microscope and CBCT scanning as an objective analytic tool to ascertain root canal morphology.

## References

1. Kulild JC, Peters DD. Incidence and configuration of canal systems in the mesiobuccal root of maxillary first and second molars. *J Endod* 1990;16:311–7.
2. Buhrey LJ, Barrows MJ, BeGole EA, et al. Effect of magnification on locating the MB2 canal in maxillary molars. *J Endod* 2002;28:324–7.
3. Gopikrishna V, Bhargavi N, Kandaswamy D. Endodontic management of a maxillary first molar with a single root and a single canal diagnosed with the aid of spiral CT: a case report. *J Endod* 2006;32:687–91.
4. Christie WH, Peikoff MD, Fogel HM. Maxillary molars with two palatal roots: a retrospective clinical study. *J Endod* 1991;17:80–4.
5. Barbizam JV, Ribeiro RG, Tanomaru Filho M. Unusual anatomy of permanent maxillary molars. *J Endod* 2004;30:668–71.
6. Ferguson DB, Kjar KS, Hartwell GR. Three canals in the mesiobuccal root of a maxillary first molar: a case report. *J Endod* 2005;31:400–2.
7. de Almeida-Gomes F, Maniglia-Ferreira C, Carvalho de Sousa B, et al. Six root canals in maxillary first molar. *Oral Surg Oral Med Oral Pathol Oral Radiol Endod* 2009;108:e157–9.
8. Dankner E, Friedman S, Stabholz A. Bilateral C shape configuration in maxillary first molars. *J Endod* 1990;16:601–3.
9. Martínez-Berná A, Ruiz-Badanelli P. Maxillary first molars with six canals. *J Endod* 1983;9:375–8.
10. Bond JL, Hartwell G, Portell FR. Maxillary first molar with six canals. *J Endod* 1988;14:258–60.
11. Maggiore F, Jou YT, Kim S. A six-canal maxillary first molar: case report. *Int Endod J* 2002;35:486–91.
12. Adanir N. An unusual maxillary first molar with four roots and six canals: a case report. *Aust Dent J* 2007;52:333–5.
13. Alavi AM, Opananon A, Ng YL, et al. Root and canal morphology of Thai maxillary molars. *Int Endod J* 2002;35:478–85.
14. Thomas RP, Moule AJ, Bryant R. Root canal morphology of maxillary permanent first molar teeth at various ages. *Int Endod J* 1993;26:257–67.
15. Hulsmann M. A maxillary first molar with two disto-buccal root canals. *J Endod* 1997;23:707–8.
16. Stone LH, Stroner WF. Maxillary molars demonstrating more than one palatal root canal. *Oral Surg Oral Med Oral Pathol* 1981;51:649–52.
17. Baratto Filho F, Zaitter S, Haragushiku GA, et al. Analysis of the internal anatomy of maxillary first molars by using different methods. *J Endod* 2009;35:337–42.
18. Cobankara FK, Terlemez A, Orucoglu H. Maxillary first molar with an unusual morphology: report of a rare case. *Oral Surg Oral Med Oral Pathol Oral Radiol Endod* 2008;106:e62–5.
19. de la Torre F, Cisneros-Cabello R, Aranguren JL, et al. Single-rooted maxillary first molar with a single canal: endodontic retreatment. *Oral Surg Oral Med Oral Pathol Oral Radiol Endod* 2008;106:e66–8.
20. Newton CW, McDonald SA. C-shaped canal configuration in a maxillary first molar. *J Endod* 1984;10:397–9.
21. De Moor RJ. C-shaped root canal configuration in maxillary first molars. *Int Endod J* 2002;35:200–8.
22. Yilmaz Z, Tuncel B, Serper A, et al. C-Shaped root canal in a maxillary first molar: a case report. *Int Endod J* 2006;39:162–6.

23. Malagnino V, Gallottini L, Passariello P. Some unusual clinical cases on root anatomy of permanent maxillary molars. *J Endod* 1997;23:127–8.
24. Fava LR. Root canal treatment in an unusual maxillary first molar: a case report. *Int Endod J* 2001;34:649–53.
25. Ma L, Chen J, Wang H. Root canal treatment in an unusual maxillary first molar diagnosed with the aid of spiral computerized tomography and in vitro sectioning: a case report. *Oral Surg Oral Med Oral Pathol Oral Radiol Endod* 2009;107:e68–73.
26. Gopikrishna V, Reuben J, Kandaswamy D. Endodontic management of a maxillary first molar with two palatal roots and a single fused buccal root diagnosed with spiral computed tomography - a case report. *Oral Surg Oral Med Oral Pathol Oral Radiol Endod* 2008;105:74–8.
27. Chen IP, Karabucak B. Conventional and surgical endodontic retreatment of a maxillary first molar: unusual anatomy. *J Endod* 2006;32:228–30.
28. Poorni S, Kumar A, Indira R. Maxillary first molar with aberrant canal configuration: a report of 3 cases. *Oral Surg Oral Med Oral Pathol Oral Radiol Endod* 2008;106:e53–5.
29. Aggarwal V, Singla M, Logani A, et al. Endodontic management of a maxillary first molar with two palatal canals with the aid of spiral computed tomography: a case report. *J Endod* 2009;35:137–9.
30. Christie WH, Peikoff MD, Fogel HM. Maxillary molars with two palatal roots: a retrospective clinical study. *J Endod* 1991;17:80–4.
31. Di Fiore PM. A four-rooted quadrangular maxillary molar. *J Endod* 1999;25:695–7.
32. Baratto-Filho F, Fariniuk LF, Ferreira EL, et al. Clinical and macroscopic study of maxillary molars with two palatal roots. *Int Endod J* 2002;35:796–801.
33. Cecic P, Hartwell G, Bellizzi R. The multiple root canal system in the maxillary first molar: a case report. *J Endod* 1982;8:113–5.
34. Holtzman L. Multiple canal morphology in the maxillary first molar: case reports. *Quintessence Int* 1997;28:453–5.
35. Johal S. Unusual maxillary first molar with 2 palatal canals within a single root: a case report. *J Can Dent Assoc* 2001;67:211–4.
36. Holderrieth S, Gernhardt CR. Maxillary molars with morphologic variations of the palatal root canals: a report of four cases. *J Endod* 2009;35:1060–5.
37. Favieri A, Barros FG, Campos LC. Root canal therapy of a maxillary first molar with five root canals: case report. *Braz Dent J* 2006;17:75–8.
38. Beatty RG. A five-canal maxillary first molar. *J Endod* 1984;10:156–7.
39. Stabholz A, Friedman S. Endodontic therapy of an unusual maxillary permanent first molar. *J Endod* 1983;9:293–5.
40. Wong M. Maxillary first molar with three palatal canals. *J Endod* 1991;17:298–9.
41. Patel S, Dawood A, Whaites E, et al. New dimensions in endodontic imaging: part I. Conventional and alternative radiographic systems. *Int Endod J* 2009;42:447–62.
42. Robinson S, Czerny C, Gahleitner A, et al. Dental CT evaluation of mandibular first premolar root configurations and canal variations. *Oral Surg Oral Med Oral Pathol Oral Radiol Endod* 2002;93:328–32.
43. Farman AG. ALARA still applies. *Oral Surg Oral Med Oral Pathol Oral Radiol Endod* 2005;100:395–7.
44. Scarfe WC. Imaging of maxillofacial trauma: evolutions and emerging revolutions. *Oral Surg Oral Med Oral Pathol Oral Radiol Endod* 2005;100:875–96.
45. Ballal S, Sachdeva GS, Kandaswamy D. Endodontic management of a fused mandibular second molar and paramolar with the aid of spiral computed tomography: a case report. *J Endod* 2007;33:1247–51.
46. Reuben J, Velmurugan N, Kandaswamy D. The evaluation of root canal morphology of the mandibular first molar in an India population using spiral computed tomography scan: an in-vitro study. *J Endod* 2008;34:212–5.
47. Kalender WA, Siessler W, Koltz E, et al. Spiral volumetric CT with single-breath-hold technique, continuous transport and continuous scanner rotation. *Radiology* 1990;173:567–8.
48. Patel S, Dawood A, Ford TP, et al. The potential applications of cone beam computed tomography in the management of endodontic problems. *Int Endod J* 2007;40:818–30.
49. Nair MK, Nair UP. Digital and advanced imaging in endodontics: a review. *J Endod* 2007;33:1–6.
50. Cotton TP, Geisler TM, Holden DT, et al. Endodontic applications of cone-beam volumetric tomography. *J Endod* 2007;33:1121–32.
51. Tyndall DA, Rathore S. Cone-beam CT diagnostic applications: caries, periodontal bone assessment, and endodontic applications. *Dent Clin North Am* 2008;52:825–41.
52. Matherne RP, Angelopoulos C, Kulild JC, et al. Use of cone-beam computed tomography to identify root canal systems in vitro. *J Endod* 2008;34:87–9.
53. Lofthag-Hansen S, Huuomonen S, Grondahl K, et al. Limited cone-beam CT and intraoral radiography for the diagnosis of periapical pathology. *Oral Surg Oral Med Oral Pathol Oral Radiol Endod* 2007;103:114–9.
54. Mah JK, Danforth RA, Bumann A, et al. Radiation absorbed in maxillofacial imaging with a new dental computed tomography device. *Oral Surg Oral Med Oral Pathol Oral Radiol Endod* 2003;96:508–13.
55. Gijbels F, Jacobs R, Bogaerts R, et al. Dosimetry of digital panoramic imaging. Part I: patient exposure. *Dentomaxillofac Radiol* 2005;34:145–9.

56. Ludlow JB, Davies-Ludlow LE, Brooks SL, et al. Dosimetry of 3 CBCT devices for oral and maxillofacial radiology: CB Mercuray, NewTom 3G and i-CAT. *Dentomaxillofac Radiol* 2006;35:219–26.
57. Brooks SL. Effective Dose of Two Cone-Beam CT Scanners: I-CAT and NewTom 3G. *Quarterly Publication of the American Association of Dental Maxillofacial Radiographic Technicians*. Winter 2005.
58. Patel S. New dimensions in endodontic imaging: part 2. Cone beam computed tomography. *Int Endod J* 2009;42:463–75.
59. Vertucci FJ. Root canal anatomy of the human permanent teeth. *Oral Surg Oral Med Oral Pathol Oral Radiol Endod* 1984;58:589–99.
60. Sert S, Bayirli GS. Evaluation of root canal configurations of the mandibular and maxillary permanent teeth by gender in the Turkish population. *J Endod* 2004;30:391–8.