

Preparation of Oval-shaped Root Canals in Mandibular Molars Using Nickel-Titanium Rotary Instruments: A Micro-computed Tomography Study

Frank Paqué, Prof. Dr. med dent,* Marc Balmer, med dent,* Thomas Attin, Prof. Dr. med dent,* and Ove A. Peters, DMD, MS, PhD[†]

Abstract

Introduction: This study evaluated the prepared surface areas of oval-shaped canals in distal roots of mandibular molars using four different instrumentation techniques. **Methods:** Teeth were prescanned and reconstructed using micro-computed tomography (MCT) scans at low resolution (68 μm). Forty-eight molars with ribbon-shaped/oval distal root canals were selected and randomly assigned to four groups. Distal canals ($n = 12$ each) were prepared by circumferential filing using Hedström files to apical size #40 (group H/CF); with ProTaper nickel-titanium rotaries to finishing file 4 (F4) considering the distal canal as 1 canal (group PT/1); ProTaper to F4 considering buccal and oral aspects of the distal canal as 2 individual canals (group PT/2); ProTaper to F4 in a circumferential filing motion (PT/CF). Before and after shaping, teeth were evaluated using MCT at 34- μm resolution. The percentage of prepared surface was assessed for the full canal length and the apical 4 mm. Statistical analysis was performed using analysis of variance and Bonferroni/Dunn multiple comparisons. **Results:** Preoperatively, canal anatomy was statistically similar among the groups ($p = 0.56$). Mean (\pm standard deviation) untreated areas ranged from 59.6% (± 14.9 , group PT/2) to 79.9% (± 10.3 , PT/1) for the total canal length and 65.2% to 74.7% for the apical canal portion, respectively. Canals in group PT/1 had greater untreated surface areas ($p < 0.01$) than groups PT/2 and PT/CF. Among all groups, amounts of treated surface areas were statistically similar in the apical 4 mm. **Conclusions:** Preparations of oval-shaped root canals in mandibular molars left a variable portion of surface area unprepared regardless of the instrumentation technique used. However, considering oval canals as two separate entities during preparation appeared to be beneficial in increasing overall prepared surface. (*J Endod* 2010;36:703–707)

Key Words

Micro-computed tomography scans, nickel-titanium instruments, oval root canals, root canal preparation

One of the major procedural steps in endodontic treatment is to thoroughly remove debris, pulp tissue, and microorganisms from the root canal system by means of chemomechanical preparation (1). To this end, it has been suggested to prepare canals to a homogenous tapered shape with the prepared canal including the preoperative outline (1, 2). However, the root canal system is anatomically complex, and mechanical instrumentation may result in preparation errors. Moreover, the use of both conventional hand files and current nickel-titanium (NiTi) rotary instruments does not result in a fully prepared root canal surface (3).

A funnel-shaped canal with a circular base is not the common configuration in root canal anatomy (2). Recently, cross-sectional root canal configurations have been classified as round, oval, long oval, flattened, or irregular (4). Metrically, Jou et al (4) defined “oval” as having a maximum diameter of up to 2 times greater than the minimum diameter and “long oval” as having a maximum diameter of 2 to 4 times greater than the minimum diameter.

A high prevalence of oval and long oval root canals even in the apical root canal portion has been reported (5–7). According to Wu et al (5), the prevalence of long-oval root canals in the apical third of human teeth is generally about 25%; in some groups of teeth such as lower incisors and upper second premolars, the prevalence is greater than 50%, and in distal roots of lower molars, the prevalence is 25% to 30%. This complex anatomy may be regarded as one of the major challenges in infection control through root canal preparation.

One aim in the preparation of infected root canals is to remove the inner layer of dentin (8). This aim is particularly hard to achieve when preparing long oval root canals. Furthermore, after preparation, uninstrumented recesses may be left in many oval canals, irrespective of the instrumentation technique, thus leaving debris and unprepared root canal surfaces behind (8–13).

Various instrumentation techniques have been recommended to facilitate the preparation of oval root canals (13). The most common technique using hand instruments is circumferential filing with K-type or Hedström files. After the introduction of rotary NiTi instruments, laboratory research on extracted teeth has also addressed their ability to shape oval root canals (12). However, in that study, rotary instruments, even if used in a circumferential filing motion, were not superior compared with hand instrumentation techniques. More recently, the use of rotary instruments with taper larger than 4% was shown to be more efficient than hand files in preparing oval root canals (14). However, the tapered NiTi instruments used in that study were unable to completely prepare oval root canal walls.

The previously mentioned studies were performed on roots of extracted teeth, which were sectioned before the preparation of the root canals. Then, root cross-sections were assessed before and after preparation, thus representing

From the *Division of Endodontology, University of Zurich Dental School, Zurich, Switzerland; and [†]Department of Endodontics, University of The Pacific, Arthur A. Dugoni School of Dentistry, San Francisco, CA, USA.

Address requests for reprints to Dr Frank Paqué, University of Zurich Dental School, Plattenstr. 11, CH-8028 Zurich. E-mail address: frank.paque@zmk.uzh.ch. 0099-2399/\$0 - see front matter

Copyright © 2010 American Association of Endodontists.
doi:10.1016/j.joen.2009.12.020

two-dimensional analyses. In contrast, the technique of micro-computed tomography (MCT) scanning allows a complete description of three-dimensional effects that root canal preparation exerts on root canal anatomy without altering the root during the experiments (3). This research tool allows calculation of the root canal area that is not mechanically prepared and remains as a so-called untreated surface (15).

Untreated canal surface area may be used as a three-dimensional measure for the completeness of a root canal shape, depending on the instrument and canal type (16). Therefore, the aim of the current study was to evaluate the prepared surface areas of oval-shaped root canals in mandibular molars using different instrumentation techniques.

Materials and Methods

From teeth that had been extracted for reasons unrelated to the current study, a total of 200 human mandibular molars were collected. Distal roots were inspected under a stereomicroscope to verify that they had only one main portal of exit. The remaining 100 molars were pre-scanned using MCT (μ CT 20; Scanco Medical, Brüttisellen, Switzerland) at a resolution of 68 μ m. Based on a slice-by-slice assessment taking the distal root apex as a reference point, the slice 6-mm coronal of the apex was determined and the root canal at that level outlined. The minimum diameter of the root canal was measured mesio-distally, and the maximum diameter was measured buccolingually using measurement tools included in the MCT software. Only teeth with a canal ratio of long to short diameter (D_l/D_s) of more than 2 were selected for further investigations; teeth were stored in 0.1% thymol solution at 4°C until further use.

Access to the pulp chamber was gained, and the distal root canals orifice was inspected. Irrigation was performed with 2.5% NaOCl using a 27-G needle and a 2-mL syringe. Root canals showing a single oval orifice were instrumented with K-files size #10 until the tip was just visible at the apex. After subtracting 1 mm of this length a radiograph (Digora; Soredent, Helsinki, Finland) was exposed in the buccolingual direction with a K-file (Dentsply Maillefer, Ballaigues, Switzerland) in place to verify working length and to determine canal curvature. Based on measurements according to Schneider's method (17), teeth with a root canal curvature less than 20° were selected. Thus, a total of 48 teeth remained, fulfilling all the mentioned criteria. The root canals were stratified according to the canal ratio and then randomly assigned to the four experimental groups. Canal ratio means in the four groups ranged from 3.88 to 3.93 and were statistically similar.

Teeth were subsequently mounted on scanning electron microscopy stubs and scanned at an isotropic resolution of 34 μ m using previously established methods (15, 16). Precise repositioning of pre- and postpreparation images was ensured by a combination of a custom-made mounting device and a software-controlled iterative superimposition algorithm (18, 19); resulting color-coded root canal models (green indicates preoperative and red postoperative canal surfaces) enabled metric comparison of the matched root canals before and after shaping.

All canals were prepared by a clinician (MB) who had more than 3 years experience in root canal preparation techniques including the use of Hedström files and NiTi rotaries. He also had completed an extensive training period using ProTaper Universal instruments (Dentsply Tulsa Dental, Tulsa, OK) and had been instructed in the use of Hedström files for circumferential filing.

The operator was not allowed to see reconstructed root canal models before preparation commenced so as to avoid bias by an attempt to manually direct preparation instruments into any potentially uninstrumented area. Distal canals ($n = 48$) were instrumented in four experimental groups ($n = 12$ each) as follows: in group H/CF, using Hedström files (Dentsply Maillefer) in a circumferential filing motion,

the coronal part of the root canal was preflared circumferentially using Gates-Glidden-drills sizes 4, 3, and 2 into the transition of the coronal and middle root canal third. For subsequent root canal preparation, Hedström files beginning with size #10 were placed to working length and were then moved in a filing motion along the long oval root canal at least twice as suggested by Wu et al (13). This was done until reaching a master apical file size of #40. Care was taken in all experimental groups that a reservoir of irrigation solution was present in the root canal system in order to maintain cutting efficacy of hand and rotary files.

In the three remaining groups, ProTaper instruments (Dentsply Maillefer, Ballaigues, Switzerland) were used up to the finishing file F4 in a sequence according to the manufacturers' guidelines. In group PT/1, distal root canals were prepared considering the canal as one canal with a passive insertion of the rotary without any preferred lateral direction. In group PT/2, distal root canals were prepared considering buccal and oral aspects each as two individual canals. In group PT/CF, ProTaper instruments were used in a circumferential filing motion. Similar to the Hedström files used in the H/CF group, each file was worked along the long oval root canal three times. For group PT/1, additional circumferential filing (similar to the procedure carried out in group H/CF) was performed using Hedström files sizes #30 to #40 subsequent to the first MCT evaluation. After canal shaping was completed, canals were irrigated with a final sequence of 2.5% NaOCl, 17% EDTA, and 2.5% NaOCl (5 mL each).

Before and after shaping, virtual root canal models were reconstructed based on the MCT scans. From individual canal models, overall canal volumes from apical foramen to the furcation level as well as canal volumes in the apical 4 mm were determined using previously established methods (16, 18). Similarly, using superimposed canal models, the percentage of unprepared canal surface was determined for the full canal length and the apical 4 mm.

Data were normally distributed, and, therefore, statistical analysis was performed using analysis of variance followed by Bonferroni/Dunn multiple comparisons. Where appropriate, repeated-measures analysis of variance and pair-wise t tests were used. Regression analysis was used to correlate canal dimension with the amount of untreated surface. A level of $\alpha = 0.05$ was considered significant.

Results

Preoperatively, there were no differences regarding overall and apical canal volumes among experimental groups ($p = 0.56$), indicating adequate randomization. Root canal preparation of distal root canals resulted in increased volumes ($p < 0.001$) with no significant differences among groups. Neither a ProTaper rotary instrument nor a Hedström file fractured in any of the experimental groups.

Figure 1 shows representative examples of superimposed root canal models before and after canal preparation. In all specimens, some areas of unprepared canal walls were detected indicated by green color coding. The fraction of uninstrumented root canal surface was not correlated to the canal ratio D_l/D_s ($r = 0.024$, $p > 0.05$; Fig. 2A).

Mean untreated areas ranged from 59.6% (± 14.9) in group PT/2 to 79.9% (± 10.3) in group PT/1 (Fig. 2B). Analysis of variance showed that the difference in the untreated surface area among groups was significant ($p < 0.01$). When the apical sections were analyzed separately, the mean untreated areas ranged from 65.2% (± 18.7 and 24.0, respectively) in groups PT/2 and PT/CF to 74.7% (± 17.2) in group H/CF (Fig. 2C); there were no significant differences among groups in the apical 4-mm section. Additional circumferential filing with Hedström files (similar to PT/CF) in group PT/1 decreased the fraction of uninstrumented area to 69.1% \pm 9.2% ($p < 0.01$) but left still more root canal wall untreated than in group PT/2.

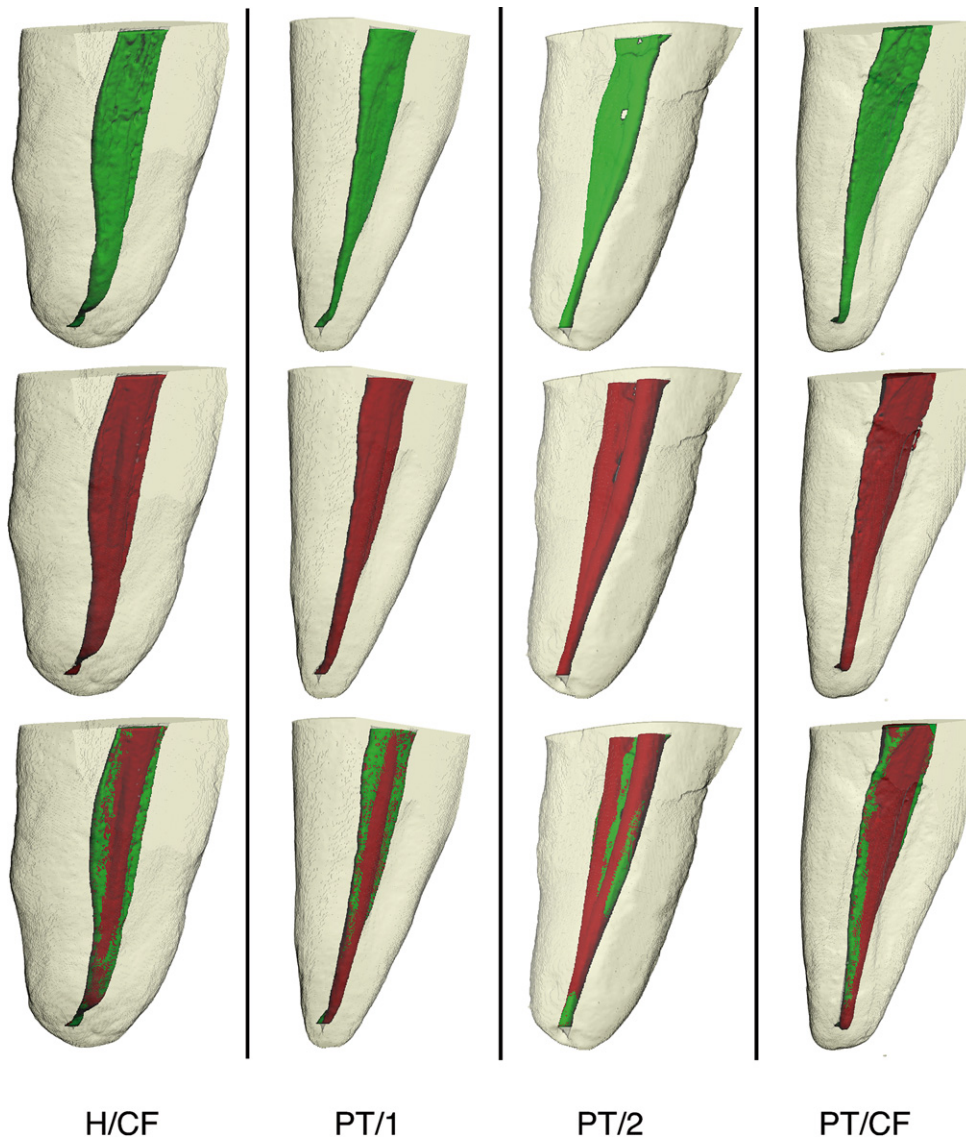


Figure 1. Panel with reconstructed models of distal roots of mandibular molars, representative for groups H/CF, PT/1, PT/2 and PT/CF. Green color indicates preoperative surfaces (top row), red color indicated postoperative surfaces (middle row). Superimposition (bottom row) illustrates amount and localization of uninstrumented areas. Roots are shown from the proximal aspect. Note that all techniques leave some root canal surface area uninstrumented.

Discussion

The main aim of this study was to compare commonly recommended methods to prepare root canals with long-oval cross section based on MCT reconstructions. Distal root canals in mandibular molars represented an adequate model for the present experiment, with a mean diameter ratio of 1:3.91 even at the 6-mm level. The present data suggest that the preparation of nonround canals leaves some canal surface uninstrumented. This finding was not related to the preparation strategy, and its extent was only weakly correlated to preoperative canal anatomy. However, when such oval canals are prepared as if there were 2 separate buccal and lingual canals, preparation with rotary instruments was more efficient than with hand instruments.

The present study is the first to quantify in a nondestructive manner the ability of rotary instruments to prepare canal walls of root canals with a long oval cross-section. The methodology has been used extensively in studies detailing preparation outcomes with various rotary instruments in maxillary molars. In that tooth group, shaping outcomes appeared to be correlated with preoperative anatomy determined by

canal volume (15, 16). However, long oval cross-sections present a unique challenge in mandibular molars.

Admittedly, the number of canals included in each group ($n = 12$) is comparatively low, and, hence, the standard deviation of the parameter “untreated canal surface” is relatively high. On the other hand, very stringent inclusion criteria were applied, and the study was carefully controlled; therefore, the demonstrated effect of canal preparation strategy on shaping outcomes appears to be robust.

Earlier studies (8, 12, 14) used destructive two-dimensional methods to determine the amount of prepared surface. This fact alone complicates direct comparisons to the present study, which uses nondestructive three-dimensional assessments. Moreover, the methodology used in the present study describes the three-dimensional removal of material by the change in surface voxels, requiring on average the preparation of at least $34 \mu\text{m}$ of dentin to register as “prepared surface.” Weiger et al (12) showed that when any amount of preparation was included between 44% and 68% of the canal surface was unprepared in long oval canals.

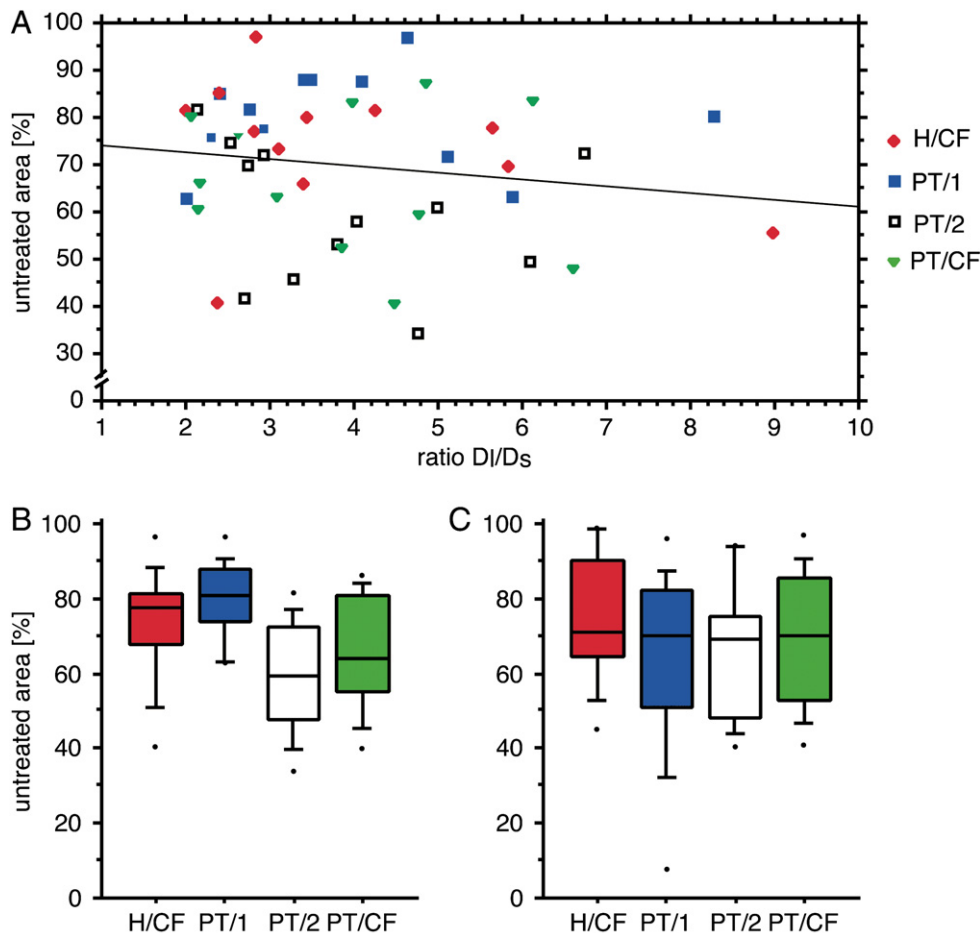


Figure 2. Relationship of percentage of unprepared canal surface to canal cross-section and preparation. Scattergram *A* shows no correlation between unprepared area and the canal diameter ratio D_1/D_s ($r^2 = 0.024$). Preparation with rotary instruments while interpreting an oval cross section as two canals resulted in less unprepared area than preparing one canal (boxplots in *B*, $p < 0.01$). There were no differences among the shaping strategies in the amount on unprepared surface in the apical 4 mm (boxplots in *C*).

In a recent study, the same group found less unprepared canal perimeter for canal shapes created with rotary instruments, ranging from 25% to 35%. However, when material removal of 200 μm was required, 80% or more of the canal surface was not counted as “prepared” (14). Compared with other studies performed on maxillary molar canals assessed with MCT (15, 16), unprepared areas in lower molar root canals in the present study were higher, indicating a particular difficulty in shaping long-oval canals. This is particularly true for the apical canal section, in which up to three quarters of the canal surface area remained unprepared in the present study.

Root canal disinfection appears to be critical for endodontic outcomes (20); eradication of microorganisms occurs as a combination of mechanical preparation (21) and irrigation (22). Irrigation alone is not always effective, and mechanical action of instruments on canal walls, including removal of infected dentin and placement of disinfecting medication such as calcium hydroxide, may be desirable (23). Both the mechanical effect of disinfection and irrigation efficacy depend on canal enlargement.

Mechanical disinfection can also be related to the removal of a layer of infected dentin, at least of incompletely mineralized predentin (24). It has been shown, however, that bacteria may penetrate dentinal tubules to depths of 200 μm and more (25). The present study indicated more than 50% of canal surface has undergone less than 34 μm of dentin removal in long-oval root canals.

Antibacterial efficacy was not determined in the present study. Mechanical preparation may affect bacterial biofilms (26) more than microorganisms in their planktonic state; it seems desirable to quantify the amount of removed biofilm using MCT. With further improvement in hard- and software, such analyses may be feasible in the near future.

In conclusion, preparations of oval-shaped root canals in mandibular molars left a high percentage of canal surface unprepared, regardless of the instrumentation technique used. However, considering such canals as two separate entities during preparation seemed to be beneficial. Regardless of the techniques used, in the present study, we noted limited mechanical preparation in the apical 4 mm, confirming the need for additional chemical disinfection.

References

1. Quality guidelines of endodontic treatment: consensus report of the European Society of Endodontology. *Int Endod J* 2006;9:21–30.
2. Schilder H. Cleaning and shaping the root canal. *Dent Clin North Am* 1974;18: 269–96.
3. Peters OA. Current challenges and concepts in the preparation of root canal systems: a review. *J Endod* 2004;30:559–67.
4. Jou Y-T, Karabuchak B, Levin J, et al. Endodontic working width: current concepts and techniques. *Dent Clin North Am* 2004;48:323–35.
5. Wu MK, R’Oris A, Barkis D, et al. Prevalence and extent of long oval canals in the apical third. *Oral Surg Oral Med Oral Pathol Oral Radiol Endod* 2000;89:739–43.

6. Mauger MJ, Schindler WG, Walker WA. An evaluation of canal morphology at different levels of root resections in mandibular incisors. *J Endod* 1999;24:607–9.
7. Gani O, Visvisian C. Apical canal diameters in the first upper molar at various ages. *J Endod* 1999;25:689–91.
8. Wu M-K, Wesselink PR. A primary observation on the preparation and obturation of oval canals. *Int Endod J* 2001;34:137–41.
9. Baroni Barbizam JV, Fariniuk LF, Marchesan MA, et al. Effectiveness of manual and rotary instrumentation techniques for cleaning flattened root canals. *J Endod* 2002;28:365–6.
10. Grande NM, Plotino G, Butti A, et al. Cross-sectional analysis of root canals prepared with NiTi rotary instruments and stainless steel reciprocating files. *Oral Surg Oral Med Oral Pathol Oral Radiol Endod* 2007;103:120–6.
11. Rödiger T, Hülsmann M, Muhge M, et al. Quality of preparation of oval distal root canals in mandibular molars using nickel-titanium instruments. *Int Endod J* 2002;35:919–28.
12. Weiger R, El Ayouti A, Löst C. Efficiency of hand and rotary instruments in shaping oval root canals. *J Endod* 2002;28:580–3.
13. Wu M-K, van der Sluis LW, Wesselink PR. The capability of two hand instrumentation techniques to remove the inner layer of dentine in oval canals. *Int Endod J* 2003;36:218–24.
14. El Ayouti A, Chu AL, Kimonis I, et al. Efficacy of rotary instruments with greater taper in preparing oval root canals. *Int Endod J* 2008;41:1088–92.
15. Peters OA, Schönenberger K, Laib A. Effects of four Ni-Ti preparation techniques on root canal geometry assessed by micro computed tomography. *Int Endod J* 2001;34:221–30.
16. Paqué F, Ganahl D, Peters OA. Effects of root canal preparation with 6 different nickel-titanium instruments on apical geometry assessed by micro computed tomography. *J Endod* 2009;35:1056–9.
17. Schneider SW. A comparison of canal preparations in straight and curved root canals. *Oral Surg Oral Med Oral Pathol* 1971;32:271–5.
18. Peters OA, Laib A, Rüegsegger P, Barbakow F. Three dimensional analysis of root canal geometry using high resolution computed tomography. *J Dent Res* 2000;79:1405–9.
19. Paqué F, Laib A, Gautschi H, Zehnder M. Hard-tissue debris accumulation analysis by high-resolution computed tomography scans. *J Endod* 2009;35:1044–7.
20. Haapasalo M, Endal U, Zandi H, et al. Eradication of endodontic infection by instrumentation and irrigation solutions. *Endod Topics* 2005;10:77–102.
21. Byström A, Sundqvist G. Bacteriologic evaluation of the efficacy of mechanical root canal instrumentation in endodontic therapy. *Scand J Dent Res* 1981;89:321–8.
22. Estrela C, Blitzkow G, Figueredo JAP, et al. Antibacterial efficacy of intracanal medications on bacterial biofilms: a critical review. *J Appl Oral Sci* 2009;17:1–7.
23. Nair PN, Henry S, Cano V, et al. Microbial status of apical root canal system of human mandibular first molars with primary apical periodontitis after “one-visit” endodontic treatment. *Oral Surg Oral Med Oral Pathol Oral Radiol Endod* 2005;99:231–52.
24. Siqueira JF Jr, Araujo MC, Garcia PF, et al. Histological evaluation of the effectiveness of five instrumentation techniques for cleaning the apical third of root canals. *J Endod* 1997;23:499–502.
25. Love RM, Jenkinson HF. Invasion of dentinal tubules by oral bacteria. *Crit Rev Oral Biol Med* 2002;13:171–83.
26. Burleson A, Nusstein J, Reader A, et al. The in vivo evaluation of hand/rotary/ultrasound instrumentation in necrotic, human mandibular molars. *J Endod* 2007;33:782–7.